



Rotary vs. Reciprocal Endodontics


Gordon's Clinical Bottom Line: Endodontic treatment is a major and increasing portion of the activity of general dentists. Root canal debridement has evolved from hand instrumentation to rotary to reciprocal instrumentation, each of which method has its proponents and opponents. Recently, some dental manufacturing companies have produced both rotary and reciprocal instruments, which further confounds the decision for dentists to determine which they want to use. *This report will assist you to compare hand, rotary, and reciprocal instrumentation and to determine if you desire to change your technique.*

Both rotary and reciprocal systems for root canal debridement are popular and successful (see *Clinicians Report*, May 2011). Each technology has advantages and limitations supported by the observation that some companies provide both types of instruments. Both methods are used in conjunction with hand files and can significantly speed up and simplify the cleaning and shaping portion of the procedure. Hand files are still used for such tasks as initial scouting; establishing the glide path and working distance; recapitulating and establishing patency during the procedure; following sharply curved canals; or when subtle feel is required.

Rotary and reciprocal are similar in that both use rotary side-cutting action, and files typically have more loosely spiraled flutes. Reciprocal systems reverse direction on each oscillation, which reduces the buildup of stresses in both the file and the tooth.

This report includes a CR survey on hand, rotary, and reciprocal instrumentation; a discussion, comparison, and research on the three methods; examples of popular systems; clinical tips; and CR conclusions.

Continued on page 2



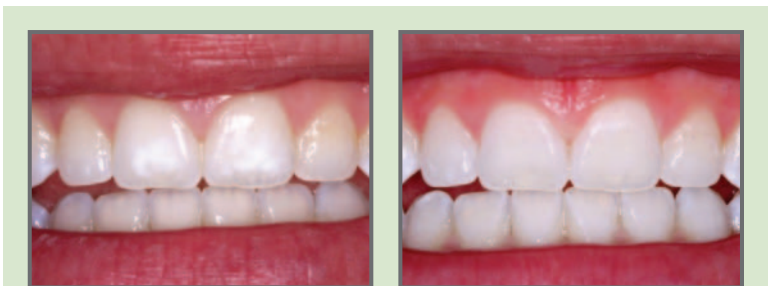When Should You Use Microabrasion for Enamel Discolorations?

Gordon's Clinical Bottom Line: Many patients have esthetically objectionable spots of various colors on their teeth. Some are demineralized areas caused by initial caries and some are hypermineralized related to trauma or exposure to chemicals during tooth development. The incidence of so-called "orthodontic white spots" is pandemic, and almost every person receiving orthodontic treatment has at least some of these demineralized areas. Various treatments have been accomplished by dentists including ceramic veneers, direct resin veneers, or just cutting the white spots off. However, one of the procedures that needs more use because of its conservative and more permanent nature is enamel microabrasion, which is mainly a staff-oriented procedure that is easy, fast, and relatively predictable. *This report will help you to compare the numerous techniques available for removing tooth discolorations and motivate you to consider and implement enamel microabrasion.*

Enamel microabrasion removes some of the enamel surface by agitation of dilute hydrochloric (*muriatic*) acid on the tooth surface, thus removing the shallow, objectionable, discolored spots. In doing so, numerous questions arise that are discussed in this report. Among them are:

- Is enamel microabrasion a dangerous procedure?
- How much enamel can be safely removed?
- What dilution of hydrochloric acid should be used?
- Does spot removal continue after the clinical spot removal appointment?
- Is it better than other spot removal procedures?
- What are the best commercial products?
- What part of the technique can be delegated to staff?
- Will benefit companies pay for it?

In this report, CR Evaluators and research staff provide a simple, easy microabrasion technique to remove tooth discolorations; a comparison of seven methods to treat discolorations; clinical tips; and research on microabrasion.



Significant "white spots" on central incisors, removed entirely by enamel microabrasion

Continued on page 3

Noteworthy Products

GripStrip:

Fast, effective finishing and polishing in one strip with easy-to-grip ends. (Page 6)



HemoStyp:

Lower-cost aid to hemostasis with this dissolvable cellulose gauze. (Page 6)



Rotary vs. Reciprocal Endodontics (Continued from page 1)

User Survey

CR survey comparing practitioner opinions concerning hand, reciprocal, and rotary endodontic techniques. Respondents n = 831

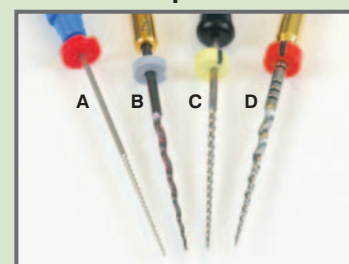
- Endodontic instrumentation used most:
 - Rotary 62%
 - Hand 27%
 - Reciprocal 11%
- In your observation, how well does each method debride canals? (scale 1–10; 10 excellent debridement, 1 poor debridement)
 - Reciprocal 9.05
 - Rotary 8.59
 - Hand 8.02
- When using each method of instrumentation, what is your anxiety level about breaking files? (scale 1–10; 10 high anxiety, 1 low anxiety)
 - Reciprocal 3.27
 - Hand 3.65
 - Rotary 5.20
- How often do you break files? (scale 1–10; 10 frequently, 1 infrequently)
 - Reciprocal 1.99
 - Hand 2.06
 - Rotary 2.42
- Ease of use rating
 - Reciprocal: 92% simple, 8% moderately difficult, 0% difficult
 - Rotary: 77% simple, 22% moderately difficult, 1% difficult
 - Hand: 51% simple, 46% moderately difficult, 3% difficult
- Planning to change from reciprocal? Yes 5% No 95%
- Planning to change from rotary? Yes 8% No 92%
- Planning to change from hand? Yes 25% No 75%
- Plan to change to:
 - Rotary 60%
 - Reciprocal 40%
 - Hand 0%

CR Analysis of File Motion

Hand, rotary, and reciprocal files all use a combination of in and out and rotary motion to debride and shape the canal.

- Hand files** are inserted and rotated to engage and cut the dentin, then withdrawn to rasp away tooth structure. Hand motions are often described as “pecking” and “watch-winding.” Files are tightly spiraled and cut mainly during the out-stroke.
- Rotary files** spin in one direction (usually clockwise) and are flexed against canal walls for an efficient milling action while being withdrawn. Typical operating speeds are 150–500 revolutions per minute (rpm). Hand motions are often described as “brushing” or “stroking.” A light touch is needed upon insertion to avoid binding file into canal. Some electric handpieces have torque limiters which can stop and reverse the file, reducing the risk of breaking the file (file separation).
- Reciprocal files** oscillate with clockwise and counterclockwise rotation each cycle. They are flexed against canal walls for an efficient milling action while being withdrawn. “Brushing” and “sweeping” hand motions are similar to rotary. Typical operating speeds of air motors are 1500–3000 cycles per minute (cpm). **New reciprocal technology** (WaveOne by Dentsply) oscillates farther counterclockwise (150°) than clockwise (30°) resulting in one complete revolution for every three oscillation cycles (-600 cpm combined with 200 rpm).

Example Files



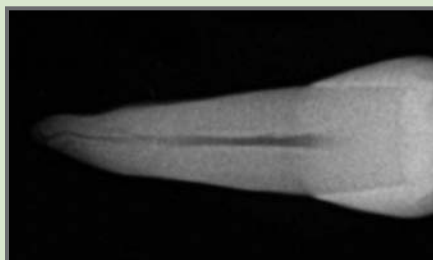
A: AET stainless steel hand file
B: HyFlex NiTi rotary file
C: SafeSider stainless steel reciprocal file
D: WaveOne NiTi reciprocal file

CR Tests on Canal Debridement and Shaping

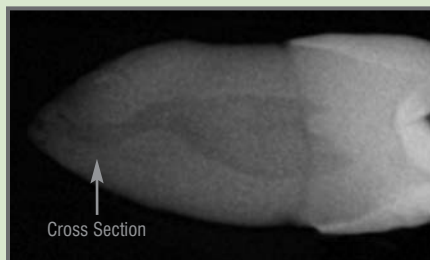
Rotary and reciprocal systems were shown to effectively prepare canals in clinical field evaluations and controlled tests using extracted teeth. CR researchers could not conclusively determine if one system was always more effective or efficient than the other. Canal anatomy (sharply curved, wide, blocked, etc.) was a significant factor. While more efficient than hand files, rotary and reciprocal systems did not mitigate the need for proper technique. Proper irrigation for chemical dissolution and cleaning of canals was also crucial, and time saved would be well devoted to more thorough irrigation. **Overall, clinical technique appeared to be more important than the endodontic system used.**

EXAMPLE OF CHALLENGING CASE

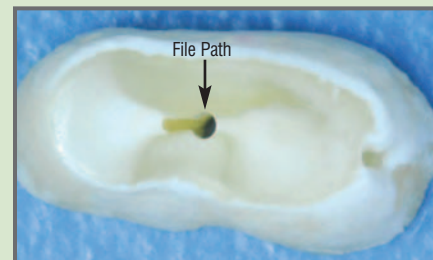
A wide and curved canal in the lower third of the root is revealed by a mesial-distal radiograph. After negotiating the curve, a reciprocating file followed a straight line to the apex without debriding the facial portion of the canal. The missed area would not be apparent in a typical facial-lingual radiograph.



Facial-lingual view



Mesial-distal view



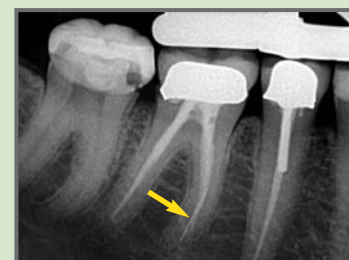
Cross section of prepared canal

CR Tests on File Separation

The risk of file separation causes anxiety for clinicians and may discourage general dentists from attempting difficult cases. Reciprocal systems can reduce the mechanical stresses that break files.

- Breakage of rotary and reciprocal files:** In vitro tests of rigidly bound files showed rotary systems frequently separated the files (even with built-in torque limiters), and reciprocal systems did not.
- Torsion stresses:** In vitro tests of torsion stresses showed reciprocal systems produced lower average stress on the tooth than did rotary systems.
- Tendency of the file to “grab” and “screw in”:** Treatment of extracted teeth showed that reciprocal systems reduced this tendency, making it easier to gently progress down the canal.
- All systems (including hand files) could experience file separation:** Clinical data and treatment of extracted teeth showed increased file breakage in sharply curved or narrow canals, and when heavy pressure was applied.
- Other factors that contribute to file separation:** weakening of the file due to multiple uses, bending, unwinding, and autoclaving.

File separation was not eliminated by any system. If file is left in canal, inform patient and note in record.


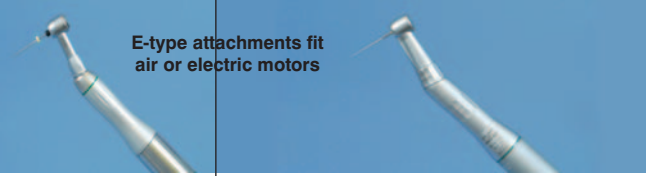








Broken file in molar root. Patient was pregnant at the time so informed decision was to not immediately retrieve file, as would be preferred.

Rotary vs. Reciprocal Endodontics (Continued from page 2)

Systems and Files Evaluated

Representative popular and newly introduced systems and files were evaluated for this study. Product information is shown below.

System	 <p>Electric motor and handpiece</p>			 <p>E-type attachments fit air or electric motors</p>		
	e ³ Torque Control Motor Dentsply			Endo-Express Essential Dental Systems	Endo-Eze Ultradent	
Cost/System	\$1,631/System: handpiece, electric motor, and programmable controller			\$804/System: handpiece and air motor	\$1,300/System: handpiece and air motor	
Motion	Reciprocal -150°/+30°	Rotary	Rotary	Reciprocal +30°/-30°	Reciprocal +30°/-30°	Reciprocal +30°/-30°
Files	WaveOne NiTi Dentsply	ProTaper NiTi Dentsply	HyFlex NiTi Coltene/Whaledent	SafeSider Stainless steel/NiTi EDS	Endo-Eze AET Stainless steel Ultradent	Endo-Eze TiLOS Stainless steel/NiTi Ultradent
						
Approximate File Cost	\$18.60 each (single use)	\$9.60 each (single use)	\$11.40 each (multiple use)	\$5.40 each (multiple use)	\$4.00 each (multiple use)	\$5.00 each (multiple use)

Clinical Tips

- **Establish glide path** with a hand file before beginning rotary or reciprocal debridement.
- **Lubricate** with EDTA solution (~15%) and frequently irrigate with sodium hypochlorite solution (~3%) during debriding and shaping process.
- **Gently move in and out of canal** with rotary and reciprocal files while simultaneously sweeping or brushing around sides, allowing rotary action to do cutting. Apply pressure against sides of canal walls during the up-stroke to prevent file tip from ledging.
- **Bend files** to help negotiate tight curves and debride beyond curves. If necessary, finish with a hand file bent to shape.
- **Do not linger with file at working depth**; side cutting can cause rapid canal widening or transportation (*opening out the side of the apex*).
- **Do not rush**; spend time to properly clean, shape, and irrigate canal for best long-term success.

CR Conclusions: Rotary and reciprocal endodontic systems use rotary milling action to efficiently debride and shape canals. Reciprocal systems were slightly preferred by users and reduced the risk of file separation. All systems evaluated performed adequately when proper techniques were used. If clinicians are achieving good results with their current system, there is no compelling reason to change. **Clinicians looking to expand or simplify their endodontic capabilities should closely consider reciprocal technology.**

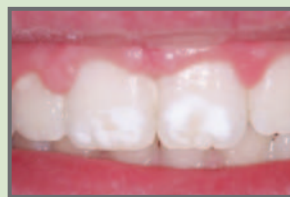When Should You Use Microabrasion for Enamel Discolorations? (Continued from page 1)

Microabrasion Technique

Techniques for microabrasion vary, and all can be successful if patient selection is correct. The following step-by-step procedure is one that is safe, effective, and most of it can be delegated to qualified, educated staff persons. The only portions of the procedure that legally require the dentist are the steps when acid is used to remove the spots:

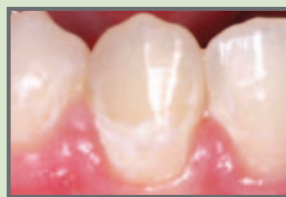1. **Patient selection:** Select only patients who appear to be viable candidates (*figures 1-5*).
2. **Patient education:** Involve patient in decision on best procedure.
3. **Informed consent:** If result not predictable, advise of potential restoration need.
4. **Operating field:** Dry field necessary, rubber dam best, ligate dam to move it apically with floss if spots close to gingiva. Dam may not be necessary in some situations if spots *not* close to gingiva.
5. **Eye protection:** Paper towel or glasses on patient's eyes.
6. **Plaque/stain removal:** Remove surface contaminants or acid will not work without abrasive agitation.
7. **Obtain acid paste/slurry:** Proven example commercial products: Opalustre by Ultradent or PREMA by Premier. *See clinical tips on making your own slurry.*
8. **Place acid slurry on teeth:** Put slurry on tooth/teeth for one minute without agitation.
9. **Agitate acid slurry:** Using soft "ribbed" rubber cup at about 500 rpm, rotate cup for one minute on tooth/teeth allowing slurry to remove spots. Don't overdo agitation; acid removes significant tooth structure (*see graph on page 6*).
10. **Wash acid slurry off:** Observe the spot(s). If gone, go to next step. If not gone, repeat process. Two or three applications are usually adequate.
11. **When are you finished?** If spots not completely removed, be aware there is an unpredictable continuing disappearance of some of the remaining spots over the next several days. Dismiss patient, and observe again in about one week.

Figure 1: Microabrasion Possible



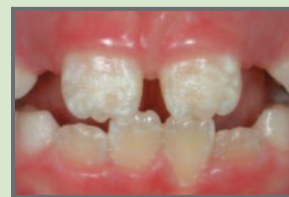White spots apparently caused by trauma to tooth bud during tooth development

Figure 2: Microabrasion Possible



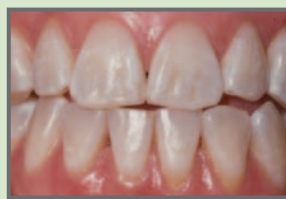Orthodontic demineralization

Figure 3: Microabrasion Possible



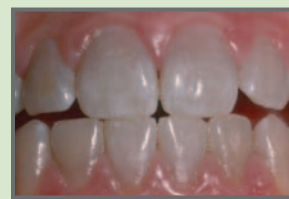Turner's hypoplasia

Figure 4: Microabrasion Questionable



Microabrasion may show yellow tooth color as small white spots are removed. Try bleach first.

Figure 5: Microabrasion Not Indicated



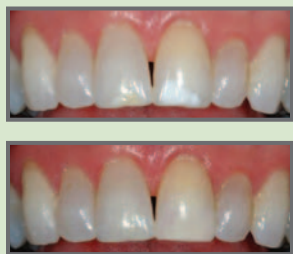Microabrasion may remove minor white surface color, making grey color worse. Try bleaching or crowns.

12. **Smoothing etched tooth surface:** Can be done with several increasingly fine grits of prophylactic paste followed by composite polish.
13. **Application of fluoride:** When spot(s) are removed, place 5000 ppm fluoride gel for five minutes (*example: Prevident 5000 by Colgate*).
14. **Sensitivity:** Warn patient that mild tooth sensitivity may be present for a few days.
15. **The ADA code** for enamel microabrasion is D9970. Benefit companies may pay.

When Should You Use Microabrasion for Enamel Discolorations? (Continued from page 3)

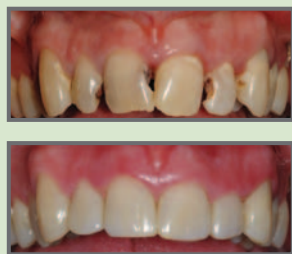Conservative to Aggressive Methods to Treat Tooth Discolorations (See techniques 1–7 below)

Figure 6: Enamel Microabrasion



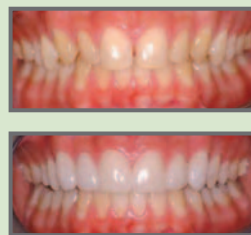Significant “white spot” on central incisor, probably caused by trauma to primary teeth during permanent tooth development. Spot entirely removed from central incisor by enamel microabrasion.

Figure 7: Resin-based Composite Veneers



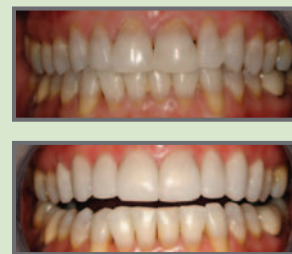Gross dental caries and tooth discoloration treated with resin-based composite restorations covered with thin resin veneering material

Figure 8: Thin Ceramic Veneers



Unsightly yellow teeth in lingual version, covered successfully with thin, no-prep ceramic veneers

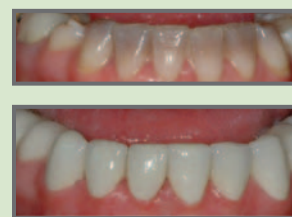Figure 9: Ceramic Veneers



Tetracycline staining on all teeth related to delivery of antibiotic at about 2–3 years of age. Teeth were bleached. Note lack of homogeneous bleach on lower teeth. Standard thickness (0.5 mm to 0.75 mm thick) ceramic veneers were placed on upper anterior and first premolar teeth.

- 1. Bleaching/whitening teeth:** Least aggressive technique that will satisfy many clinical situations. Delay restorative dentistry for at least two weeks which allows some color to return to bleached teeth.
- 2. Impregnation of resin into acid-etched tooth surfaces:** A new technique under investigation may treat demineralized areas and carious lesions with acid and impregnates resin into tooth surface (*Icon from DMG America*).
- 3. Enamel microabrasion** (figures 1–3 on page 3 and figure 6 above): Very conservative procedure. Consider if clinical situation appears to warrant this approach. Minimally invasive and permanent.
- 4. Resin-based composite veneers** (figure 7): Either full facial surface veneers or partial veneers that just cover the affected area(s) are relatively conservative, inexpensive, and effective. Well-proven example products that remain smooth during service are: Durafill (*Heraeus Kulzer*), Renamel Microfill (*Cosmedent*), Estelite Sigma Quick (*Tokuyama America*), Filtek Supreme Ultra (*3M ESPE*), and Herculite Ultra (*Kerr*). Patients should be advised that this treatment has a viable service life of only a few years before marginal discoloration or breakage occurs.
- 5. Thin ceramic veneers** (figure 8): Popularized a few years ago by “Lumineers” (*DenMat*), this concept is viable for some clinical situations, including teeth not significantly discolored with the following characteristics:
 - Small teeth
 - Teeth in lingual version
 - Teeth with diastemas
- 6. Standard thickness ceramic veneers** (figure 9): If moderate discolorations or malpositioned teeth, 1/2 to 3/4 mm of tooth structure can be removed and ceramic veneers placed. Covering severe stains with veneers is often not adequate because of need for extreme opaquing to prevent color showing through the veneer.
- 7. Full crowns** (figure 10): When stains are severe, crowns are the best and most predictable option.

Figure 10: Crowns



Deep tetracycline stain on incisor teeth. Full-ceramic crowns were placed. They serve better than veneers in such situations.

Clinical Tips

- **Superficial orthodontic “white spots.”** Don't try to eliminate too soon. Use 0.2% neutral sodium fluoride mouthrinse (*Prevident Dental Rinse, Colgate*) and/or 5000 ppm toothpaste (*ClinPro 5000, 3M ESPE*) for a few months after removal of orthodontic resin. This often reduces or removes white spots.
- **When deciding to attempt to remove the spots,** make sure they appear to be only superficial, less than 1/2 mm deep. Clinical experience soon allows you to judge this depth.
- **Removing minute, white fluorosis spots.** Some easy to remove, others not easy with microabrasion. Some fluorosis spots are tiny white speckles on the teeth. From a distance teeth look white; close up they have white “freckles” (figure 3 on page 3). When these spots are removed, the teeth often look yellow. Bleaching teeth with these minute white spots is usually better than trying to remove them since the underlying enamel color is then closer in color to the white spots.
- **Being too conservative.** If it is doubtful that the conservative techniques will be adequate, suggest to the patient a more aggressive technique.
- **Dark, homogeneous, total tooth discolorations.** Enamel microabrasion is not indicated. Crowns are the most predictable solution (figure 10 above).
- **Making your own material for enamel microabrasion.** It has been suggested that you may make your own slurry by buying muriatic acid from a hardware store, diluting the solution with water until it is about 6% hydrochloric acid, and mixing flour of pumice with it until it is a putty-like material. *CR research showed that this technique did not remove enamel as rapidly as commercial products, but it was effective.* Some commercial products contain silicon carbide (*carborundum*) which is more aggressive than flour of pumice.

Continued on page 6

CE Self-Instruction Test—September 2012

“Clinical Success is the Final Test”

- 1 Earn Up to 11 Credit Hours.** Receive 1 credit hour for successful completion of each month’s test (*January 2012 through November 2012*). This is a self-instruction program. CR Foundation is an ADA CERP recognized provider and an AGD approved PACE program provider.
- 2 Complete the Test.** Tests for each issue of Clinicians Report are available online at www.CliniciansReport.org or by calling 888-272-2345.

CE Self-Instruction Test—September 2012 *Check the box next to the most correct answer*

Take your CE test online and receive immediate results!
www.CliniciansReport.org

1. Which of the following statements is *most correct*?
 - A. Rotary and reciprocal files eliminate the need for hand files.
 - B. Rotary and reciprocal files primarily cut with their end, like a drill.
 - C. Rotary and reciprocal files can simplify and speed up the shaping process.
 - D. Rotary and reciprocal files have more tightly spiraled flutes than hand files.
2. Which statement is *false*, based on the user survey?
 - A. Rotary is used more than hand and reciprocal technology.
 - B. Most hand file users plan to change.
 - C. Reciprocal was rated easiest to use.
 - D. File separation anxiety was greatest for rotary users.
3. Which statement *accurately* describes file motions?
 - A. Rotary files spin quickly, faster than 10,000 rpm.
 - B. Reciprocal files oscillate slowly, less than 60 cpm.
 - C. Hand files are only moved in and out of the canal, never rotated.
 - D. The WaveOne system reciprocates and rotates.
4. Which of the following statements is *true*?
 - A. Reciprocal systems usually cause file separation.
 - B. Rotary systems usually clean canals better than reciprocal.
 - C. Reciprocal systems reduce the risk of file separation.
 - D. Rotary and reciprocal systems eliminate the need for canal irrigation.
5. Enamel microabrasion is indicated for:
 - A. Tetracycline stains
 - B. Shallow, discolored spots
 - C. Deep small spots of any color
 - D. Carious areas deeper than 1/2 mm
6. Muriatic acid is:
 - A. Dilute sulfuric acid
 - B. Dilute hydrochloric acid
 - C. Dilute acetic acid
 - D. None of the above
7. Use of a rubber dam when doing enamel microabrasion is:
 - A. Always indicated
 - B. Indicated if the spots are near the incisal area of the tooth/teeth
 - C. Indicated if the spots are near the gingival area of the tooth/teeth
 - D. Never indicated
8. Enamel microabrasion discoloration removal is:
 - A. Permanent
 - B. Mostly staff oriented
 - C. Simple
 - D. Easy
 - E. All of the above
9. Significant advantages of GripStrip are:
 - A. Wide, perforated ends improve grip
 - B. Two grits on the same strip: one for stripping and one for polishing
 - C. Center section without grit for easier insertion
 - D. All of the above
10. HemoStyp is a gauze that aids hemostasis and is made of:
 - A. Chemically treated collagen
 - B. A combination of collagen and cellulose
 - C. Cellulose
 - D. Cellulose with hemostatic chemicals

3 Print Participant Information.

 For additional participants, photocopy this page and list requested information.

Name _____ Email _____
 Address _____ Phone _____
 City _____ State _____ ZIP _____

Please send my tests results directly to the Academy of General Dentistry. (AGD# _____)

4 Annual Enrollment Fee for 2012.

 Select one:

Payment Method: Visa MC AMEX Discover Check (*Payable to CR Foundation®*)

- \$88 Clinicians Report Subscriber
- \$108 non-subscriber
- Already enrolled

Cardholder’s Signature _____ Exp. _____ CID _____
(Signature Required)

5 Send your test answers and enrollment fee to: Clinicians Report Fax: 888-353-2121 or Mail: 3707 N Canyon Rd, Bldg 7, Provo UT 84604

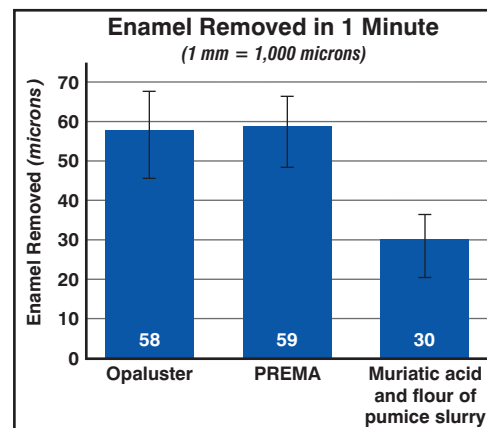
To receive credit, all 2012 tests are due by
December 15, 2012

When Should You Use Microabrasion for Enamel Discolorations? (Continued from page 4)

CR Research on Enamel Removal

Research protocol: CR researchers tested three formulations: Opalustre (*Ultradent*), PREMA (*Premier*), and a homemade muriatic acid/flour of pumice slurry (*6% hydrochloric acid*). A 1 mm layer of material was applied to tooth and worked into enamel for 60 seconds using a slow-speed prophy cup. Teeth were rinsed and measured to determine the amount of enamel removed. Additionally, the effect of polishing the treated surface was observed under a scanning electron microscope (*SEM*).

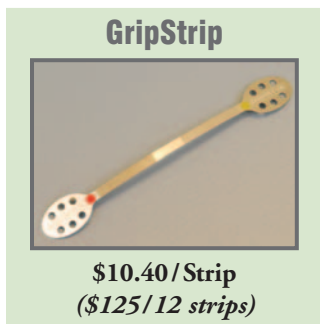Results: Both Opalustre and PREMA removed similar amounts of enamel (*approximately 60 microns/minute; 0.1 mm = 100 microns*). The muriatic acid/flour of pumice slurry (*6% hydrochloric acid*) proved less aggressive (*30 microns/minute*) than commercially available products. Enamel removal rate varied greatly from tooth to tooth. Clinicians should monitor enamel removal and expect to see variations from patient to patient. Treated surfaces were smoothed with coarse, medium, and fine prophy paste (*Nupro by Dentsply*) followed by a composite polish (*Enamelize by Cosmedent*), which produced increasingly smooth surfaces.



CR Conclusions: Enamel microabrasion of esthetically objectionable superficial spots on teeth is a conservative, simple, fast, and effective procedure for *some* types of discolorations. Experience is required to determine which type of discoloration can be removed easily. Patients should receive information about microabrasion before clinicians suggest more aggressive procedures such as resin or ceramic veneers or crowns.

Noteworthy Products (Continued from page 1)

Fast, Effective Finishing and Polishing in One Strip with Easy-to-Grip Ends



GripStrips are diamond-coated interproximal strips with two working areas of different grit sizes in one strip (*40 μm grit for stripping and removing material, and 15 μm grit for polishing*). The two areas are color coded (*red 40 μm, yellow 15 μm*) and separated by a non-coated center in the strip which aids insertion. Wide, perforated ends provide a more secure grip. GripStrips are autoclavable and reusable.

Advantages:

- Wide, perforated ends improved grip
- Easy to use
- Good length of strip
- Two grits on one strip for finishing and polishing with one insertion
- Center section was thin and easy to pass through most contacts

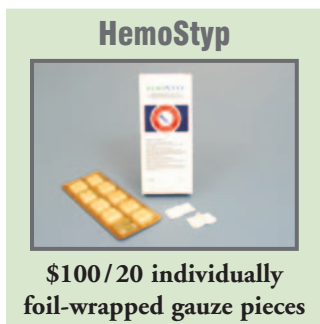Limitations:

- A few CR Evaluators desired serrated edge on the center, grit-free section
- Only one length available

Centrix
800-235-5862 • www.centrixdental.com

CR Conclusions: 92% of 24 CR Evaluators stated they would incorporate GripStrip into their practice. 92% rated it excellent or good and worthy of trial by colleagues.

Lower-Cost Aid to Hemostasis with this Dissolvable Cellulose Gauze



HemoStyp is specially formulated from cellulose, has no chemicals, and produces hemostasis upon contact with the cut or wound. It may be dissolved by adding water or saline onto the gauze which allows easy removal if needed without pulling the clotted surface away and causing re-bleeding.

Advantages:

- Potential to stop bleeding quickly with good clot characteristics
- Easy to remove from packaging
- Easy to place and use
- Good size, and easy to cut if smaller size desired
- Can be dispensed to patient
- Less expensive than other similar hemostatic gauzes

Limitation:

- A few CR Evaluators commented that once moist, HemoStyp becomes sticky and may be more difficult to manipulate

Sinc Ventures
855-255-7462 • www.sincventures.com

CR Conclusions: 70% of 24 CR Evaluators stated they would incorporate HemoStyp into their practice. 83% rated it excellent or good and worthy of trial by colleagues.

Products evaluated by CR Foundation® (CR®) and reported in *Gordon J. Christensen CLINICIANS REPORT®* have been selected on the basis of merit from hundreds of products under evaluation. CR® conducts research at three levels: (1) Multiple-user field evaluations, (2) Controlled long-term clinical research, and (3) Basic science laboratory research. Over 400 clinical field evaluators are located throughout the world and 40 full-time employees work at the institute. A product must meet at least one of the following standards to be reported in this publication: (1) Innovative and new on the market; (2) Less expensive, but meets the use standards; (3) Unrecognized, valuable classic; or (4) Superior to others in its broad classification. Your results may differ from CR Evaluators or other researchers on any product because of differences in preferences, techniques, batches of products, and environments. CR Foundation® is a tax-exempt, non-profit education and research organization which uses a unique volunteer structure to produce objective, factual data. All proceeds are used to support the work of CR Foundation®. ©2012 This Report or portions thereof may not be duplicated without permission of CR Foundation®. Annual English language subscription \$149 worldwide, plus GST Canada subscriptions. Single issue \$15 each. See www.cliniciansreport.org for non-English subscriptions.